

COLUMBIA LIBRARIES OFFSITE
HEALTH SCIENCES STANDARD



HX00033618

INTRODUCTION
TO THE USE
OF THE LARYNGOSCOPE

ARCHIBALD E. GARROD

M.A., M.B.

RC786

G19



COLUMBIA UNIVERSITY
EDWARD G. JANEWAY
MEMORIAL LIBRARY

With the Author's Compliments.

AN INTRODUCTION
TO THE USE OF THE
LARYNGOSCOPE

BY

ARCHIBALD E. GARROD

M.A., M.B. Oxon., M.R.C.P.

LONDON
LONGMANS, GREEN, AND CO.
1886

All rights reserved

PRINTED BY
SPOTTISWOODE AND CO., NEW-STREET SQUARE
LONDON

Med
35-3917

RC 786


G19

TO

MY FATHER

ALFRED BARING GARROD, M.D., F.R.S.

I DEDICATE THIS LITTLE BOOK



Digitized by the Internet Archive
in 2010 with funding from
Open Knowledge Commons

P R E F A C E.



THE object of this little book is to supply a handy guide to practitioners who may wish to acquaint themselves with the use of the Laryngoscope, and to the daily increasing number of students who attend in the throat departments of our hospitals.

My best thanks are due to Mr. Butlin for much kind help and friendly criticism, and to Mr. Leonard Mark for the drawings which he has been good enough to make for me.

To the valuable lectures of Professors Schrötter and Schnitzler, of Vienna, I am indebted for many practical hints which I am sure from personal experience will be found useful by the beginner.

ARCHIBALD E. GARROD.

10 HARLEY STREET, W.
December 1885.

CONTENTS.



| CHAPTER | PAGE |
|--|------|
| I. THE LARYNGOSCOPE | 1 |
| II. THE MANNER OF USING THE LARYNGOSCOPE | 7 |
| III. DIFFICULTIES OF LARYNGOSCOPY | 15 |
| IV. THE LARYNGOSCOPIC PICTURE | 19 |
| V. ANATOMY AND PHYSIOLOGY OF THE LARYNX | 25 |
| VI. APPLICATION OF REMEDIES TO THE LARYNX | 34 |
| VII. LARYNGEAL SURGERY | 39 |
| VIII. RHINOSCOPY ANTERIOR AND POSTERIOR | 43 |
| IX. SYNOPSIS OF THE APPEARANCES IN THE CHIEF LARYN- GEAL DISEASES | 49 |

THE LARYNGOSCOPE.



CHAPTER I.

THE LARYNGOSCOPE.

ALTHOUGH Bozzini, Babington, Avery, and others had been more or less successful in the attempt to obtain a view of the larynx during life, the Laryngoscope in its present form was invented by M. Manuel Garcia in 1855. He utilised his discovery for the study of the production of the various musical tones, and did not apply it to any medical purpose. It is to Türck, of Vienna, who reinvented the instrument in 1857, and to Czermak, who introduced it to the notice of the faculty in the various European capitals, that laryngoscopy as a branch of medical science owes its origin.

The laryngoscope of the present day differs in no essential points from the original instruments of Garcia and Türck, although experience and good workmanship have introduced many improvements. The essential part of the instrument is a small plane mirror, usually made of a circular form, mounted in a frame of German silver or some other suitable metal, and supported by a wire stem, which is fixed into a convenient handle. The metallic mirrors which were at first employed

are now entirely superseded, for although they possessed an advantage in being readily and thoroughly cleansed, this was more than compensated by the loss of reflecting power of the steel or silver surface, due to scratching or to the action of reagents.

In the same way the rhombic, oval, and **D** shapes have been almost entirely given up in favour of the circle, which possesses the advantage of being easily rotated in the mouth cavity and of being equally efficient whether introduced with the right hand or the left. Only in those cases in which the tonsils are so greatly enlarged as to present an obstacle to the introduction of the round mirror is the oval form to be preferred.

Since the available space varies greatly in different patients, it is necessary to employ throat mirrors of various sizes. In Germany and Austria they are numbered from the smallest upwards, the numbers corresponding to the following diameters :

| | | | | | |
|-------|---|---|---|---|---------------------|
| No. 1 | . | . | . | . | $\frac{9}{16}$ inch |
| „ 2 | . | . | . | . | $\frac{3}{4}$ „ |
| „ 3 | . | . | . | . | $\frac{7}{8}$ „ |
| „ 4 | . | . | . | . | $\frac{15}{16}$ „ |
| „ 5 | . | . | . | . | 1 „ |

Nos. 1 and 2 are chiefly used for posterior rhinoscopy and for the examination of very young children, while Nos. 3 and 4 are those most generally useful for adults, and it is to these sizes that the mirrors supplied with English instruments usually correspond. The wire stem should be fairly stout, so as not to bend too easily, and should be from $2\frac{1}{2}$ to $3\frac{3}{4}$ inches in length, and fastened at an angle of 125° to the surface

of the mirror. The form of the handle is a matter of individual taste, but those in which the mirror is fixed in place by a screw will be found most convenient.

Special mirrors should be reserved for syphilitic cases, and should have some distinguishing mark. The German makers usually mark the mirrors intended for this purpose with an L stamped upon the back (for 'Lues').

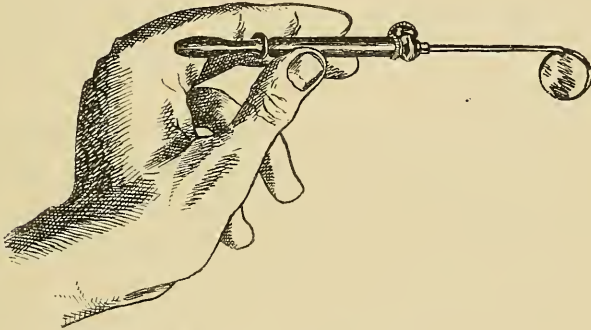


FIG. 1.—Throat Mirror.

The illumination of the parts is effected by means of a concave reflector with a central hole, which should be an actual perforation in the glass and not merely an unsilvered spot. Experience shows that the reflector should have a diameter of about $3\frac{1}{2}$ ins. and a focal distance of 8 or 9 ins. To avoid glare, the metal back of the mirror and the margins of the central hole should be blackened.

The earliest reflectors were fastened to a cross bar, which was held between the teeth of the observer, but this plan was soon given up in favour of the more convenient one of attaching it in some manner to the

head. This may be done by means of a forehead band, which has the advantage of giving a very firm support ; but it is apt to produce headache if worn continuously for a long time, as is often necessary in hospital practice. Schrötter recommends that there should be three points of support, of which the ends of a metallic plate resting upon the forehead are two, whilst a third is provided by two padded knobs fastened to an arm of the same plate, which rest upon the sides of the bridge of the nose. Unless there is this third support the forehead band possesses no advantage in point of steadiness over the other plans.

Semmeleder fastened the reflector to a stout spectacle frame, and a modification of his form is extensively used, especially in this country. In more modern instruments one half of the spectacle rim is absent, an improvement which considerably lessens the weight. Since the reflector and the stout frame are rather weighty, the ear pieces must be made to embrace the back of the concha, while the pressure upon the bridge of the nose is relieved by means of a pad.

A third form has recently been introduced into America, but has not met with general adoption. The reflector is fastened to a flat, bent spring, which embraces the vertex of the head and rests by means of pads against the forehead and occiput.

Since it is necessary that the reflector should be capable of free movement upon its support, and yet should be firmly held, the connection is made by means of a ball-and-socket joint, tightened by a screw.

Whether the reflector be worn in front of one eye or

over the forehead is a matter of individual taste. Neither plan has any particular advantage, but the relative position of observer and patient will be slightly different in the two cases, since he who wears his mirror upon his forehead must sit rather lower, in order that the rays of light may not be intercepted by the teeth.

The advantage which has been claimed for the forehead position—that it allows of binocular vision—is in reality imaginary, since in the other plan the free eye as well as the covered is used.

Since the accuracy with which anatomical details and slight pathological changes can be observed depends upon the brilliancy of the illumination, the choice of a source of light is a matter of the greatest importance to the laryngoscopist. Sunlight, when it can be employed, is by far the best for the purpose, and may be directed upon the parts by a plane reflector, or even by the ordinary concave one. With it the parts are seen in their natural colours, and all the details are brought out with great minuteness, so that slight alterations of tint or form are much more readily made out than when an artificial light source is used, unless it be the electric light, which is, however, seldom available.

Of artificial lights an Argand gas-burner is the best, especially if its efficiency be increased by a dark chimney and a bull's-eye lens.

Mackenzie's lamp, which has free lateral movement and can be raised and depressed by means of a rack, will be found very convenient where many cases are to be examined.

For bedside use a very fair illumination can be obtained from an ordinary duplex lamp, the flat sheet of flame allowing an evenly lighted disc to be thrown upon the back of the throat, whilst in emergencies it is even possible to make an examination with the aid of a candle.

The laryngoscope is of necessity a somewhat costly instrument, the usual price being about thirty shillings. The English makers usually supply a reflector with forehead band or spectacle frame and two throat mirrors for this sum, whilst a Viennese case will contain a reflector and forehead band, six throat mirrors, and two handles, as well as brushes and a sound. Of the handles the white is intended for ordinary, the black for syphilitic mirrors. These instruments are not so well finished as those made in England, but they will be found to answer all requirements satisfactorily.

Before buying an instrument the beginner should make up his mind, by trial if possible, whether he prefers the forehead band or spectacle form, and if he decide upon the latter should see that it is the lower rather than the upper part of the rim that is absent, whilst for the nasal portion a groove fitting the bridge will be found more comfortable than a pad.

CHAPTER II.

THE MANNER OF USING THE LARYNGOSCOPE.

FOR the purpose of laryngoscopic examination the observer and patient should be seated opposite to each other, the patient sitting upon a rather higher level, so that his mouth may be almost opposite to the eyes of the observer. Their faces should be separated by a distance of about two feet and a half, and the source of light should be placed over one of the shoulders of the patient, so that the rays falling upon the reflector may form a disc upon the back of his pharynx.

Before the throat mirror is introduced a careful preliminary examination of the arches of the fauces, the uvula, the hard and soft palates, and the back of the pharynx should be made, the tongue being depressed by a spatula or the handle of a mirror. This proceeding should never be omitted, since from the condition of these parts it is often possible to obtain material aid towards the diagnosis of the laryngeal trouble.

A throat mirror of suitable size should then be selected and gently warmed over the lamp. The object of this warming is to prevent the condensation of the moisture of the breath upon the reflecting surface, since the film so formed would completely destroy its

efficiency. It is important that the reflecting surface be held towards the source of heat, as that is the part which requires to be warmed, whereas if the back be heated the metal will become too hot, whilst the glass remains comparatively cool. Too great heat is apt to dull the amalgam and to impair the efficiency of the mirror, so it is well to follow the plan recommended by Dr. Mackenzie—that is, to watch until the film of moisture which is at first formed is completely dissipated, and then to cease warming. But it must be borne in mind that even then the mirror may be too hot for introduction, and its temperature should always be tested against the back of the hand.

When sunlight is used the warming may be effected by dipping the mirror into hot water ; but this method, if frequently employed, is very destructive to the amalgam, since the water is apt to soak in between the edge of the glass and the metallic rim.

When the mirror has been properly warmed, and not sooner, the patient should be requested to put out his tongue and to incline his head slightly backwards. The border of a pocket-handkerchief, or cloth specially reserved for the purpose, is laid over the tip of the tongue, which is then grasped between the thumb and fore-finger of the left hand, and gently drawn forwards by a slight rotatory movement of the wrist, the finger serving to protect the frænum from the lower teeth, which might otherwise lacerate it. The tongue should never be held during the warming of the mirror, as it is important to avoid tiring the patient more than is necessary during the preliminary stages of the examination ;

and it should be borne in mind that the neglect of such a simple rule as this betrays at once a want of familiarity with the use of the laryngoscope.

The mirror, held as a pen, should next be introduced to the back of the mouth cavity, with the reflecting surface downwards, care being taken that it does not touch the palate or tongue in its progress, since contact with the former is apt to provoke reflex movements, whilst the coating of saliva derived from the latter will dull the surface of the glass and seriously impair the image. Since the axis of the mouth cavity is not a straight line, but a curve with the convexity upwards, the mirror in its progress should be made to follow this axis--that is, should move in a curve, the wrist being depressed during the early stage and elevated as the back of the cavity is neared.

When the soft palate is approached a slight movement of rotation should be communicated to the mirror, so that the stem, which was at first uppermost and in the middle line, may come to rest against the angle of the mouth, where it does not encroach upon the line of vision. The back of the mirror should then be pressed rather firmly against the soft palate and base of the uvula, pushing it upwards; otherwise the end of the uvula will hang down below the lower border of the glass and be reflected on its surface, its image occupying a considerable portion of the field, so that the view of the deeper structures is materially interfered with.

When the mirror has once been brought into position it should be kept there, and should not be moved about over the palate in search of the larynx, nor should

it be rotated more than is necessary, since these movements tend to excite intolerance in the patient, and this intolerance is perhaps the chief obstacle to be overcome.

The art of hitting upon the correct position is only to be acquired by practice, and when this has not been accomplished it is better to withdraw and reintroduce

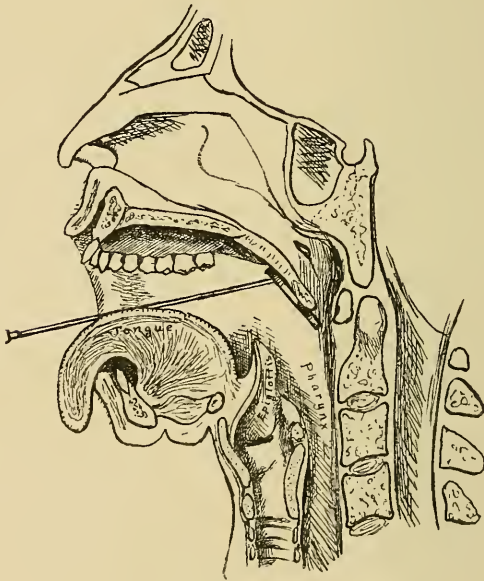


FIG. 2.—Throat Mirror in position.

the mirror than to attempt to rectify an originally faulty introduction.

The angle which the surface of the mirror should form with the horizon depends upon the optical law that the angle of incidence equals the angle of reflection, the requisite being that the rays from the reflector should be thrown from the throat mirror upon the

laryngeal orifice. The position of the larynx in the body is such that this angle will be found to be about fifty or sixty degrees. The angle will be different in different individuals, so that the utmost that can be done is so to introduce the mirror that a minimum of

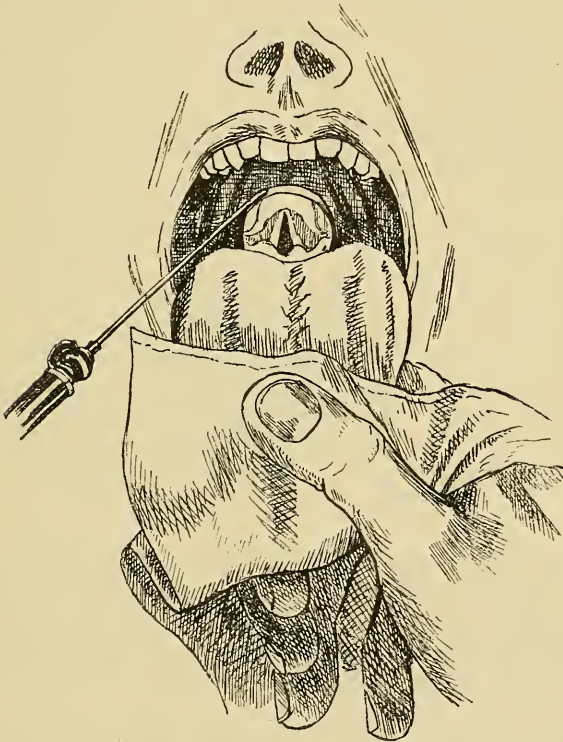

FIG. 3.—Throat Mirror in position.

movement is necessary to bring the parts into view. In searching for the image the hand holding the mirror should be raised or lowered until the proper angle is found. In a patient unaccustomed to laryngoscopic examination the introduction of the mirror is often fol-

lowed by coughing or other reflex movements, due in many cases to a feeling of apprehension, which is very soon overcome; and even very intolerant throats will often become rapidly accustomed to the examination, all difficulties disappearing in a few days. Repeated attempts at a single sitting tend, on the other hand, to tire the patient and to increase his intolerance, so the beginner should be content with a hasty glimpse of the larynx at first, reserving for another day the more detailed exploration and the establishment of his diagnosis.

At first the effort to see the larynx will occupy the entire attention, and abnormalities, unless they be very conspicuous, will probably escape notice; but as greater proficiency is attained it will be found possible to pass in review rapidly all the leading points, and to notice any peculiarities of colour or form, any irregularity of outline or impairment of mobility, which may be present.

Since it is necessary to observe not only the condition of the structures when at rest, but also the mobility of the vocal cords and arytenoid cartilages, these must be set in motion by the patient during the examination.

The cords may be brought into the phonation position by intoning the vowels *ah* or *e*, whilst during deep inspiration they are separated to their maximum extent.

Here a word of warning to the beginner is necessary, for if the mirror be held in a skew position a distortion of the image results, and one vocal cord appears to have

a perpendicular position even when the glottis is open. This distortion may prove a pitfall and lead to the diagnosis of paralysis where none exists ; but if there is any doubt it may be easily dispelled by withdrawing the mirror and reintroducing it with the left hand, a proceeding which reverses the obliquity and at once exposes the error.

Both hands should be equally accustomed to the introduction of the throat mirror, for the use of the left is necessary when remedies are topically applied or any surgical interference is called for, since the instru-

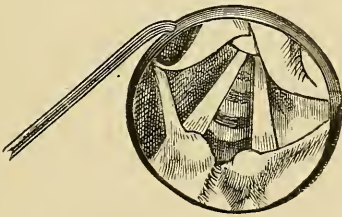


FIG. 4.—Laryngoscopic Picture in Skew Mirror.

ments employed must be introduced with the right hand under the guidance of the mirror held in the left.

The mirror should be withdrawn, as it is introduced, face downwards, in the line of the axis of the mouth cavity, and the tongue being released, the examination is concluded.

The careful and thorough cleansing of the throat mirror after use is a matter of the greatest importance, since the crevices between the glass and metal may furnish a lodging-place for contagious materials, the introduction of which into the throat of a second patient may be attended with disastrous results.

Warm water, or better still a solution of carbolic acid, should be used for the washing ; but the mirrors should not be allowed to stand in the liquid for any length of time, as the soaking in of moisture round the edges rapidly destroys them.

CHAPTER III.

DIFFICULTIES OF LARYNGOSCOPY.

ALTHOUGH the laryngoscopic examination is extremely simple in principle, the beginner will find that in practice it is beset with many difficulties. Of these the most important is the intolerance of the patient, the introduction of the throat mirror being frequently productive of violent coughing, retching, or even vomiting. Such intolerance will be greatest when there is an actual inflammatory condition of the parts, but where this is not the case it is the result of a species of nervous apprehension, which rapidly disappears as the patient becomes more accustomed to the operation. No doubt in many cases the inexperience or clumsiness of the observer is the cause, and as he becomes more proficient fewer cases of intolerance will be met with. Throats which appear to the beginner to be extremely intolerant may often be examined by those who have had more experience without any trouble, the reflex action being caused by efforts to rectify the position of a badly-placed mirror.

Cases will be met with, however, in which the posterior parts of the throat resent the introduction of the mirror to such an extent that even in the most

skilled hands a satisfactory examination is impossible ; and then it will be necessary to paint the parts with a 10 per cent. solution of cocaine, or to direct the patient to suck a piece of ice or inhale a solution of potassium bromide in the form of spray. In such cases it is often possible to obtain a glimpse of the cords by resting the mirror against the less sensitive mucous membrane of the hard palate.

The majority of patients will be found to be quite sufficiently tolerant, and in some, especially in hysterical people, the parts are so little sensitive that reflex action is not induced even by the most clumsy movements of the throat mirror against the back of the pharynx.

The epiglottis frequently presents a serious obstacle to the examination by overhanging the laryngeal orifice. This difficulty may be due to an actual anatomical condition, the so-called 'dependent epiglottis,' but more frequently it arises from a faulty position of the mirror, which has not been introduced far enough backwards and consequently stands at too obtuse an angle.

When there is a true 'dependence,' the obstacle may usually be overcome by directing the patient to intone the vowel *e* or to take a deep breath, both of which actions are accompanied by a depression of the larynx as a whole, and a consequent elevation of the epiglottis, sufficient to allow of a good view of the vocal cords. When this fails the patient should be requested to throw his head back whilst the observer, standing, looks downward into the throat, and if he meanwhile intones *ah* or *e* the parts will be brought into view in all but extreme cases.

Where all else fails, resort must be had to mechanical means of lifting. Türck and Schrötter have constructed extremely ingenious instruments for passing a thread through the epiglottis, by tension upon which it may be raised ; but beyond the natural reluctance which one must always feel to resort to such means, the operation, although simple in theory, is by no means easy in practice, and even when the thread has been successfully passed tension will usually merely raise the central portion whilst the sides fall together, obstructing the view as much as before, so that the obstacle is in no way removed.

Such appliances are now entirely abandoned in favour of a simple gum-elastic catheter, bent to a suitable curve and fastened into a wooden handle ; and such an instrument will be found to answer very well in those rare cases where lifting is necessary.

The grotesque shapes, usually modifications of the omega form, normal in children, which the epiglottis sometimes assumes, may offer a serious obstacle to the observer, who must be content with such glimpses as may be obtained through the available orifice, unless aid can be got from the above-described instrument.

The beginner is apt to find that a shadow is thrown upon the throat mirror by the upper teeth, the larynx remaining in darkness, although the mouth cavity is brightly illuminated. Under these circumstances the patient must be requested to throw his head farther back, or the observer should seat himself rather lower. This difficulty will be much more apt to arise if the

reflector be worn upon the forehead than if it is placed over the eye.

If the observer be seated too low, the tongue of the patient (especially if it be not held flat upon the floor of the mouth) may intercept the view, and in this case also the difficulty is easily overcome by taking a fresh hold upon the tongue or by pressing up the soft palate with the throat mirror.

CHAPTER IV.

THE LARYNGOSCOPIC PICTURE.

WHEN the throat mirror has been brought into the correct position, and a sufficiently powerful beam of light is thrown upon it by the reflector, a foreshortened image of the laryngeal orifice and the parts in its immediate neighbourhood is obtained.

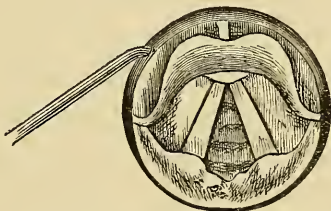


FIG. 5.—The Laryngoscopic Picture.

In this image the right vocal cord corresponds to the right cord of the patient, and the left cord to the left cord of the patient, but, owing to the obliquity of the mirror, there is a curious antero-posterior reversal of the parts. The epiglottis, on account of its greater distance from the mirror, appears posterior and in the upper part of the image, whilst the aryteno-epiglottidean folds, on account of their greater proximity to the mirror, appear anterior and in the lower part of the image. In order that he may grasp thoroughly, once

and for all, this relation of the parts, the beginner should place before him a diagram of the laryngeal orifice with the epiglottis towards him, as it would be in a patient's body. If now he place a plane mirror horizontally over the diagram, and look upwards at its reflecting surface, he will see an image of the diagram with the epiglottis towards the front, the interarytenoid fold and aryepiglottidean folds behind, the right cord on the right side, the left on the left side, but the whole diagram will be upside down. If now, as in making a laryngoscopic examination, he gradually incline the mirror to an angle of fifty or sixty degrees to the horizon, as it approaches the diagram the posterior parts are reflected in the lowest part of the mirror and appear nearest to him, while the epiglottis, which is reflected in the upper part, will appear to recede farther and farther until it comes to lie behind the interarytenoid fold. For purposes of description the picture may be conveniently divided into the intrinsic parts lying within the orifice of the larynx, the extrinsic parts forming the boundaries of that orifice, and the parts in the immediate neighbourhood.

The epiglottis forming the anterior boundary is seen edgewise, varying amounts of its anterior or posterior surface being visible according as it is more or less dependent. In colour it is yellowish, this tint being given to it by the contained plate of cartilage, whilst the vessels upon its surface stand out in rather bold contrast.

Backwards from the sides of the epiglottis extend the two aryteno-epiglottidean folds, covered with a

pink mucous membrane and usually expanded in those portions which enclose the small cartilages of Wrisberg and of Santorini, the latter of which afford convenient indices of the movements of the arytenoid cartilages, since they rest upon their apices.

The expansions corresponding to the cartilages of Wrisberg vary greatly in size in different individuals, according as the cartilages themselves are more or less developed.

During phonation the expanded extremities of the aryepiglottidean folds are brought into contact with each other, but when the vocal cords are separated the receding arytenoid cartilages open out between them a thin fold of mucous membrane, called the interarytenoid region, which encloses in its substance the arytenoid muscle, by the contraction of which the cartilages are brought into the close approximation which is necessary for phonation. The laryngeal surface of this fold is out of the reach of direct examination, and we can only arrive at a knowledge of its condition by the observation of the upper margin, which will usually appear irregular or swollen when any diseased condition of the internal surface is present; and this fact is of the greatest importance, because this region is one of those most liable to be affected in many pathological conditions.

It is obvious that swelling or thickening of the interarytenoid fold will tend to prevent the accurate apposition of the arytenoid cartilages during phonation, and by causing the cartilaginous glottis to remain partly open may lead to a considerable degree of aphonia.

Within the orifice the true and false vocal cords are seen, as well as the cushion of the epiglottis, which is a small rounded elevation at the base of that organ, and when the cords are separated a greater or less extent of the anterior wall of the trachea.

The extreme whiteness of the vocal cords, contrasting with the pink of the surrounding parts, renders them the most conspicuous objects in the laryngoscopic picture. Rising from a fixed point below the cushion of the epiglottis, they pass backwards to be inserted into the expanded ends of the aryepiglottidean folds, appearing as narrow bands, for they are overlapped to a considerable extent by the false cords or ventricular bands. It must be borne in mind that they are really of prismatic form, but only the upper surfaces of the prisms are visible in health.

The ventricular bands are folds of mucous membrane, hollowed out by the ventricles of Morgagni, two large pockets, the mouths of which appear as dark lines between the true and false cords. These cavities occasionally afford lodging-places for foreign bodies which have made their way into the larynx.

At the point of junction of the anterior two-thirds with the posterior one-third of each vocal cord is a yellowish spot which marks the attachment of some of the fibres to the tip of the vocal process of the arytenoid cartilages, the colour being due to contained elastic tissue.

The glottis, the opening left between the separated vocal cords, has a triangular shape, due to the fixation of the anterior and mobility of their posterior ends. It

is divided into two portions, known respectively as the ligamentous and cartilaginous glottis; the former being that part which is bounded by the true ligamentous cords, whilst the latter is that which lies between the vocal processes of the arytenoid cartilages. The division between the two portions is marked by the yellowish spot mentioned in the preceding paragraph.

During deep inspiration the glottis attains its maximum size, and through it the internal surfaces of the cricoid cartilage and upper rings of the trachea, and in favourable cases, with powerful illumination, even the bifurcation of the bronchi come into view.

Outside the larynx the ligaments which bind the epiglottis to the root of the tongue are easily seen, the middle ligament being separated from the two lateral by depressions called the *valleculæ*, which may be crossed by one or more accessory bands.

Towards the pharynx are two other depressions which are bounded externally by the inner surfaces of the *alæ* of the thyroid, and internally by the outer surfaces of the arytenoid cartilages, and these have been named the *sinus pyriformes*.

In the course of the examination each of the above parts should be inspected in turn. The form and colour of the epiglottis should be noticed, and the condition of the aryepiglottidean folds, whilst the mobility of the arytenoid cartilages should be tested.

The vocal cords should be examined for any breach of continuity upon their surfaces and edges, as well as for any change of tint. If they are not accurately applied to each other during phonation, an endeavour

should be made to ascertain whether the fault is due to a true paralysis or to a mechanical obstacle, such as fixation of the cartilages or swelling or ulceration of the interarytenoid fold. Lastly, when there is any suspicion of the presence of a foreign body, the valleculæ and sinus pyriformes should be carefully searched.

CHAPTER V.

ANATOMY AND PHYSIOLOGY OF THE LARYNX.

REGARDED as a musical instrument, the larynx must be placed in the reed class, since its tones are produced by two vibrating reeds, the vocal cords, and are intensified by the resonance of the mouth cavity. Its functions are, however, such as are required of no musical instrument, for not only must the same vibrating surfaces give out all the various tones which compose the scale of the human voice, but they are required to be readily set aside to allow a free passage for the ingress of the air necessary for the proper aëration of the blood in the lungs. To attain this a mechanism is required for the approximation and separation, the tightening and relaxation, of the vocal cords.

Such a mechanism is provided in a system of muscles acting upon a jointed cartilaginous skeleton, made up of nine component parts, six of which are arranged in symmetrical pairs.

Connected by a ligamentous tube with the uppermost ring of the trachea is the cricoid cartilage, which resembles a signet ring in shape, the expanded portion being posterior. On the upper border of this plate are

two facets with which the bases of the arytenoid cartilages articulate, the surfaces being held together by

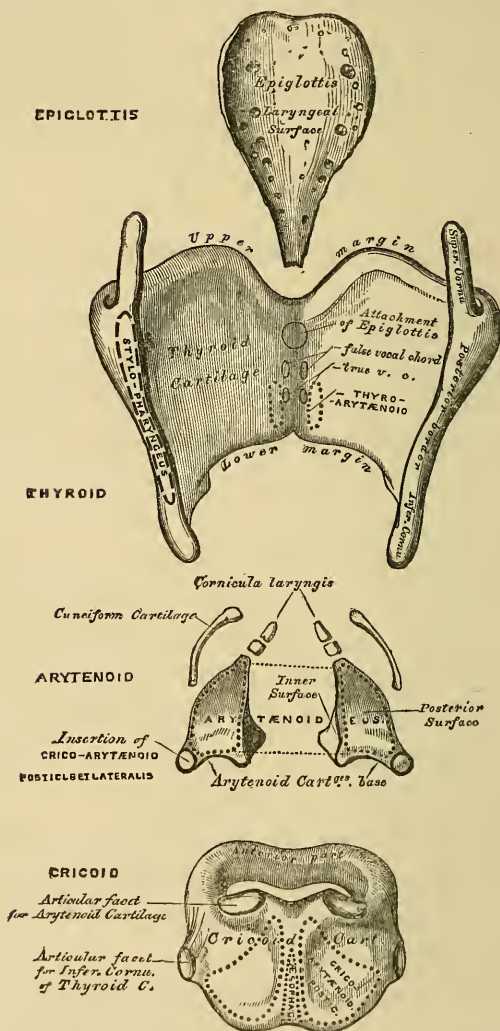


FIG. 6.—The Cartilages of the Larynx. Posterior View.
(From 'Gray's Anatomy.')

capsular ligaments, which allow of a considerable move-

ment of rotation. The œsophageal surface of the plate is divided by a central ridge into two lateral fossæ, which give insertion to a pair of important muscles.

The largest of the laryngeal cartilages is the thyroid ; it is made up of two symmetrical plates, of an irregularly quadrilateral form, which are united along the greater part of their anterior borders and diverge posteriorly, embracing the other structures of the larynx in their receding angle. The posterior margin of each plate is prolonged upwards and downwards to form the superior and inferior horns, the former of which is connected by a ligament with the great cornu of the hyoid bone, whilst the latter articulates by means of a capsular joint with a facet upon the lateral aspect of the cricoid.

The arytenoid cartilages are of a pyramidal form, and have their anterior and external basal angles prolonged into two processes, the anterior or vocal processes giving attachment to the fibres of the true cords, the external or muscular receiving the insertions of the muscles which bring about the approximation and separation of the same. Seated upon and connected by capsular joints with the apices of the pyramids are the two small cartilages of Santorini, or the cornicula laryngis, whilst the folds of mucous membrane which stretch between the edges of the epiglottis and the arytenoids are supported by the minute elastic cuneiform cartilages, or cartilages of Wrisberg.

The epiglottis contains in its substance a cartilage which resembles an obovate leaf in form, which is marked on its surface by numerous pits in which mu-

cous glands are lodged. It is attached by its stalk to the inner surface of the thyroid angle by means of the thyro-epiglottic ligament.

The larynx as a whole is suspended from the hyoid bone by the thyro-hyoid ligaments and membrane, which consist of a flat membrane stretching between the lower border of the hyoid and the upper border of the thyroid, and two lateral cords uniting the cornua.

The laryngeal tube is completed by the flat crico-thyroid membrane, which closes in the space between the lower border of the thyroid and the anterior part of the cricoid, and at the same time allows of their approximation to each other. It consists of a central and two lateral portions, which are continued above to join the fibrous structure of the vocal cords.

The superior and inferior thyro-arytenoid ligaments lie in the substance of the false and true cords respectively, the superior consisting merely of a few fibres included by the mucous folds of the ventricular bands, whilst the inferior form a great part of the substance of the cords and furnish their vibrating borders.

The elevation and depression of the larynx as a whole is effected by the contraction of the external muscles arising from the hyoid bone and sternum, viz. the sterno-hyoid, omo-hyoid, sterno-thyroid, and thyro-hyoid.

The approximation and separation of the vocal cords, which are necessary in order that the larynx may at various times serve as an organ of voice or as a channel for the ingress and egress of air, are brought about by the contraction of several pairs of muscles which act

upon the arytenoid cartilages. These cartilages act as levers of the first kind, the power being applied through the muscular, the resistance through the vocal processes, whilst the crico-arytenoid joints serve as fulcra. It will be obvious that any force tending to draw the muscular

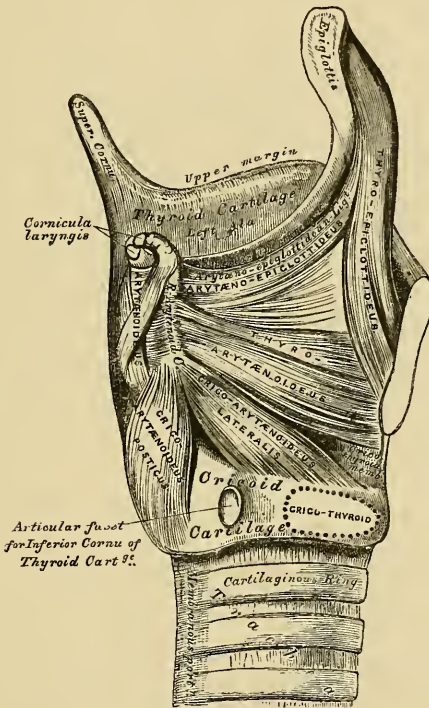


FIG. 7.—Muscles of Larynx. Side View. Right Ala of Thyroid Cartilage removed. (From 'Gray's Anatomy.')

processes forwards will tend to bring the vocal processes into contact, and so to close the ligamentous portion of the glottis. Such a force is supplied by the contraction of the lateral crico-arytenoid muscles, which arise from the sides of the cricoid and are inserted into

the tips of the muscular processes. On the other hand, any force which tends to draw the muscular processes towards the middle line will separate the vocal processes and open the ligamentous glottis.

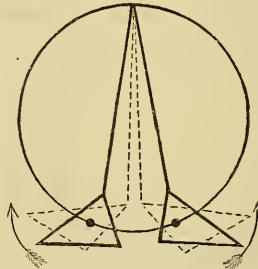


FIG. 8.—Diagram showing the action of the Lateral Adductors.

This is precisely the action of the posterior crico-arytenoid muscles, which arise from the two fossæ upon the back of the plate of the cricoid, and are inserted into the tips of the muscular processes.

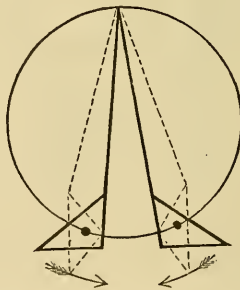


FIG. 9.—Diagram showing the action of the Abductors.

The closure of the ligamentous glottis alone is not sufficient for the production of the voice, since the cartilaginous glottis remains as a triangular aperture through which air can readily escape, and must there-

fore be closed by the approximation of the bodies of the arytenoids. This is effected by the contraction of the arytenoid muscle, which arises from the posterior aspect of the body of the one cartilage and is inserted into the corresponding portion of the other.

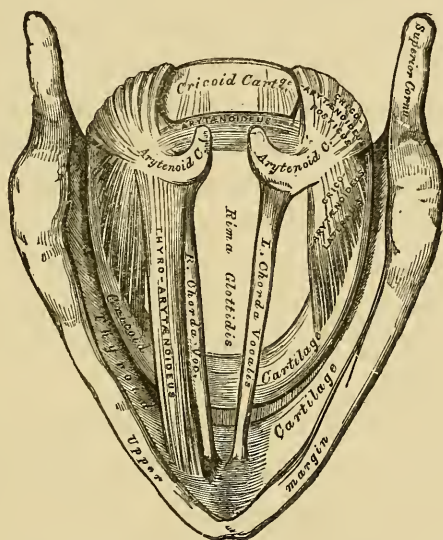


FIG. 10.—Interior of the Larynx, seen from above. (Enlarged.)
(From 'Gray's Anatomy.')

Two pairs of muscles contribute to the maintenance of that degree of tension of the cords which is required for the production of a pure note, and their mode of action is very different. The crico-thyroids, arising from the external aspects and lower borders of the alæ of the thyroid, run forward and are inserted into the front part of the cricoid. In their contraction they raise the front of the cricoid, and by so doing tend to draw the arytenoids away from the receding angle of

the thyroid, thereby placing the cords upon the stretch.

On the other hand, the thyro-arytenoids, or intrinsic muscles of the vocal cords, tend to bring the arytenoid cartilages nearer to the angle of the thyroid, and so to relax the cords, unless the arytenoids are fixed by the contraction of the other muscles, when these muscles will increase, not diminish the tension.

Each thyro-arytenoid muscle is made up of two portions, one of which, the external, lies in the aryteno-epiglottidean fold and is continued to the sides of the epiglottis, forming, with some of the diagonal fibres of the interarytenoid, a species of sphincter which serves to contract the laryngeal orifice. The second portion, the internal, lies in the substance of the cord and acts as above described.

Since the various forms of paralysis to which the cords are liable are amongst the most interesting lesions with which the laryngologist has to deal, a thorough knowledge of the nerve supply of the parts is essential to him. Fortunately it is extremely simple, for the recurrent laryngeal branch of the pneumogastric supplies all the muscles, with the exception of the crico-thyroid and some fibres of the arytenoid, the nerves of which are derived from the superior laryngeal branch.

The remarkable course of the recurrent laryngeal branch is responsible for a large proportion of all the cases of paralysis, and this is especially the case with the nerve of the left side, which, from its relation to the arch of the aorta, is particularly exposed to pressure from any aneurismal dilatation of that vessel.

Such pressure will be accompanied by loss of voice, which may lead to a laryngoscopic examination, when the cord will be seen to occupy the cadaveric ¹ position, the abductor and adductor muscles being both rendered useless.

The laryngeal muscles derive their blood supply in part from the external carotid through its superior thyroid branch, and in part from the inferior thyroid branch of the subclavian.

¹ The cadaveric position is that occupied by the cords after death—midway between abduction and adduction.

CHAPTER VI.

APPLICATION OF REMEDIES TO THE LARYNX.

UNDER the guidance of the laryngoscope it is comparatively easy to apply various remedies topically to the larynx, in many forms of disease, with the best results.

The means of doing this will be different according as the drug is to be applied in the solid or liquid form. Some solid substances, such as chromic acid, may be fused upon the end of a laryngeal sound, a rod of silver or aluminium probe-pointed and bent to the laryngeal curve or angle, and may in this way be applied directly to the desired spot. Caustic holders, of whatever construction, are more or less dangerous, since the caustic is always liable to be gripped by the contraction of the laryngeal orifice and left behind in the cavity, whence it can only be removed with great difficulty.

For powders some form of insufflator is employed, consisting of a tube of wood, glass, or ebonite, with a curved end. A piece of india-rubber tubing with a mouth-piece serves to convey the breath of the operator, which expels the powder into the larynx of the patient, whilst any backward current is stopped by a valve. The powder is introduced through a hole in the side of the tube, which can be closed by a second sliding tube, which

may be passed over it. Instruments of this construction are agreeable neither to operator nor to patient, and it is better to employ a balloon to set the air in

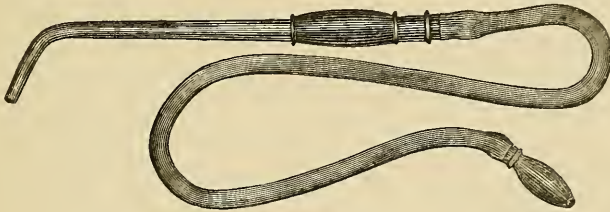


FIG. 11.—Laryngeal Insufflator with Mouthpiece.

motion, which should be connected to the insufflator by a long tube, so that it may be compressed between the knees or under the foot of the operator. If, as is often the case, the balloon be directly attached to the end of the insufflator tube, the jerk due to its compression renders the accurate application of the powder somewhat difficult.

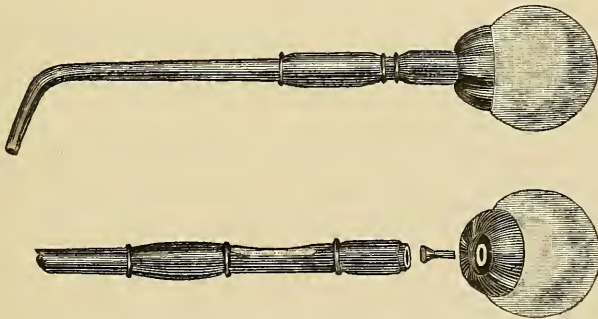


FIG. 12.—Laryngeal Insufflator.

For the proper use of this instrument it is necessary that the throat mirror should be first introduced, with the left hand; and then the insufflator, held in the right, must be guided over the border of the epiglottis, after

which a slight elevation of the handle will serve to direct its mouth towards the laryngeal orifice. This simple movement, which is necessary in all operations about the larynx, is often very difficult to acquire, and the beginner is apt to give to the instrument a forward sweep instead of merely depressing its end. The knack is best acquired by constant practice upon a well-trained larynx, with a sound, or gum-elastic catheter fixed in a suitable handle. For the application of liquids a brush or sponge will be found to answer best. The

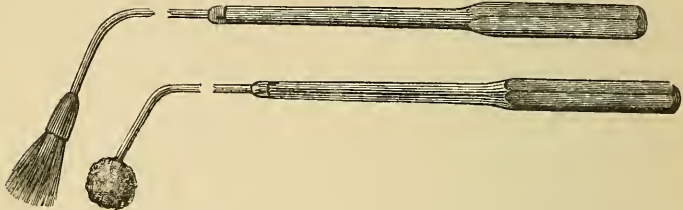


FIG. 13.—Laryngeal Brush and Sponge.

sponge is usually attached to a bent rod of whalebone, and the brush is usually fastened into a wooden socket, which may be screwed upon a wire handle. The brush should be made of squirrel's or camel's hair, and should be held securely in its socket by a rivet, since glue or cement is apt to become loosened by repeated wetting. Prof. Schrötter tells how he once left an entire brush in the larynx of a prima donna, fortunately with no evil result, as it was immediately expelled by a cough. In view of the possibility of such an accident, which may be followed by most disastrous results, all pieces of apparatus intended for introduction into the larynx should be carefully tested before use, and at once discarded if

found to be insecure. Each patient should be allotted his own special brush or sponge.

Of late years a piece of cotton wool, twisted upon a screw at the end of an aluminium sound, has come into use, and has the advantage of allowing a fresh pad to be employed for each application ; but although the wool is held very firmly there must always be some risk of its being detached.

The brush or sponge should never be introduced except under the guidance of a throat mirror. Having been dipped in the liquid to be applied, it should be gently pressed against the side of the vessel, to get rid of the superfluous liquid, and passed over the epiglottis by raising the hand as above described. The parts should be thoroughly brushed over, the patient meanwhile intoning the vowel *a*, in order that the cords may be brought in contact.

Liquids may also be introduced in the drop form by means of an instrument somewhat resembling the insufflator, from which it is expelled by the pressure of the thumb upon a tambour. Lastly, a specially constructed spray apparatus may be used, in the form of a curved tube having at the end a sphere with numerous perforations, from which jets are thrown in all directions.

For the application of vapours, inhalers are constructed, which differ in form but are identical in principle. In all there is a closed vessel provided with a mouthpiece. Heat is applied by means of a spirit lamp. The vapour is inhaled mixed with air, which is drawn through a tube dipping below the surface of the liquid, and so becomes completely saturated with vapour,

In hospital practice, where the means of the patient will not allow of the purchase of an inhaler, a sufficiently good substitute is obtained by the use of a narrow-necked jug, in which the liquid to be employed is placed together with some hot water. The mouth should be held over the mouth of the jug, so that the steam is inhaled as it rises.

CHAPTER VII.

LARYNGEAL SURGERY.

SINCE it is not always possible to form an accurate judgment of the condition of the parts by a mere inspection of the image, a sound is employed where it is desired to estimate the depth of an ulcer, the consistency of a new growth, or to test the sensibility of the mucous surface.



FIG. 14.—Laryngeal Sound.

This is simply a wire of aluminium or some other suitable metal bent to the ordinary laryngeal angle, slightly clubbed at the end, and mounted in a handle.

Before the introduction of the laryngoscope new growths could only be removed from the larynx by an external incision, and since their diagnosis was difficult the operation was but rarely performed. In the present day this is all altered. The laryngoscope allows us to see the growth *in situ* with ease, and guides the forceps which effect its removal *per vias naturales*. These

forceps are usually constructed in one of two forms. In one the stem is hollow, and from its end project two small blades, which are separated by the action of a spring, and to which are attached wires which run in the tube. By pressing forward the tube towards the blades these are approximated, and a grip of the new growth or foreign body is thus obtained. The other is simply a pair of ordinary forceps bent to the laryngeal angle and provided with scissors handles. By a slight complication of the mechanism the blades may be made to open antero-posteriorly instead of laterally. Since the parts vary in depth in different patients, forceps of various lengths and shapes will be required according to circumstances.

Instead of forceps a kind of guillotine invented by Türk may be employed. In this instrument a small ring is made to include the tumour, which is cut off by a knife blade moving across it.

When there is much œdema of the parts, scarification of the mucous membrane is often desirable. For this purpose, as well as for other cutting operations about the larynx, small guarded lancets are used, the blades of which can be exposed when the instrument has been brought into the required position. They must of course be mounted upon stems bent to the same form as the other laryngeal instruments.

For the application of electricity various methods may be employed. Either the two poles of a Faradaic battery may be held over the plates of the thyroid cartilage, or one pole may be introduced into the interior of the

larynx. For the latter purpose a specially constructed electrode, shaped somewhat like the laryngeal sound but with a larger bulb, is required, and means must be provided of turning on the current when the electrode has been brought into position.

As both of the operator's hands are occupied, one with the guiding mirror, the other with the electrode, the second pole of the battery should be fastened to a band which is worn round the patient's neck.

Before leaving the subject of laryngeal surgery reference must be made to the instruments devised for the dilatation of the contracted glottis. Of these that of Schrötter is the most successful. In this method tracheotomy is first performed, and a zinc plug is then introduced upon the end of a sound, from which it may be detached by means of a spring. The plug is triangular in section, to correspond with the shape of the opening, and at its lower end is a knob, which is grasped through the tracheotomy tube by means of a specially constructed clip which holds the plug in position. After a few hours the plug is again fastened to the sound and removed, to be reintroduced upon the following day. It is in those forms of stenosis of the larynx which are due to syphilitic disease that this method will be found to be most useful.

The various operations of laryngeal surgery demand for their successful performance a considerable facility in the introduction of instruments, which is only to be obtained by diligent practice. Such practice is best obtained by a constant use of the laryngeal sound, or

better still of a common English gum-elastic catheter fixed to a handle.

It must be borne in mind that the movements of the sound or other instrument, as seen reflected in the mirror, appear to be exactly reversed, and the beginner must learn not to be led away by this appearance.

CHAPTER VIII.

RHINOSCOPY ANTERIOR AND POSTERIOR.

No account of laryngoscopy would be complete which failed to include some description of the closely allied subject of the examination of the nasal cavity. This examination may be made either from the front or back.

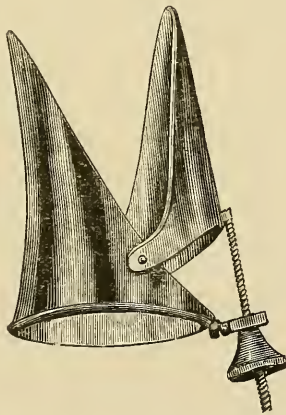


FIG. 15.—Duplay's Speculum.

In anterior rhinoscopy some kind of speculum must be used, and of such specula there are many forms. They may, however, be divided into two main varieties, viz. those, such as Fränkel's, which aim simply at the dila-

tation of the nasal orifice, and those which consist of two blades with polished internal surfaces, which serve to increase the illumination of the cavity. In Duplay's form, which is perhaps the best, a screw arrangement is provided, which allows the blades of the instrument to be gradually separated to any required extent.

The reflector should be worn by the observer, in order that the internal parts may be thoroughly illuminated. The patient must be directed to hold his head back whilst the speculum, with its blades in contact, is introduced into the nasal orifice ; the outer end is then raised so as to bring the instrument into a line with the cavity of the nares, and the blades are gradually separated until a good view is obtained. Slight movements of the patient's head, best controlled by resting the fingers upon his forehead, serve to bring the various parts into view.

The most conspicuous object in the anterior rhinoscopic picture is the anterior end of the inferior turbinated bone, which is seen projecting into the cavity. This bone can often be traced backwards for some distance, when a beam of light is thrown along the inferior meatus. To the inner side the smooth surface of the septum will be seen, covered with mucous membrane, and when the head of the patient is thrown backwards some portion of the middle turbinated bone, distinguished by the pale colour of its covering, usually comes into view in the upper part of the field.

The colour and condition of the mucous membrane covering these various parts should be carefully observed, and if this is suspected to be swollen or ulcerated

a sound should be employed to feel the consistency of the parts.

In the examination of the cavity from behind, advantage is taken of the space which is left between the soft palate and back of the pharynx during quiet respiration through the nose.

An ordinary throat mirror of the smallest size is brought to rest, face upwards, against the back of the pharynx.¹ Of late years mirrors which can be brought to any angle to their stem by pressure upon a spring have come into use, and have the great advantage of being much more easily introduced than those which allow of no such movement.

The relative positions of observer and patient should be the same as for laryngoscopy, but the head of the patient should be inclined slightly forwards instead of backwards. The tongue should be depressed by means of a spatula, preferably of the form invented by Türk. This instrument consists of an ovoid blade to which a shank is attached, and this is fastened in a handle which is held by the observer in his left hand, or even by the patient himself. The lateral position of the handle allows it to lie quite to one side, so as not to interfere at all with the illumination. In many cases it will be found quite sufficient to depress the tongue with the stem of the mirror, which may be bent to a curve corresponding to that of the dorsum.

When the movable mirror is used it should be warmed, introduced face upwards, and allowed to rest

¹ Nos. 1 and 2 of the German scale, bent to an angle of 120° to the stem, answer perfectly.

lightly upon the dorsum of the tongue. The patient is then requested to breathe quietly through the nose, a manœuvre which causes the soft palate to fall forwards, leaving a free space behind it. The mirror is then gradually inclined upon the stem (by pressure upon a spring in the handle) until an image of a portion of the posterior nares is obtained.




FIG. 16.—Posterior Rhinoscopic Mirror.

This proceeding, so simple upon paper, is by no means easy in practice, since the patient, unless he be already trained by previous attempts, will probably cough or retch to such an extent that the observation is rendered very difficult or even impossible.

A very slight degree of pharyngitis renders the

mucous membrane intensely hyperæsthetic, so that the contact of the mirror can hardly be borne.

When the ordinary fixed mirror is used it should be introduced face upwards, the handle being raised to allow of its passage through the narrow space between the tongue and hard palate. The stem is then pressed upon the dorsum linguæ, slight upward and downward movement being communicated to the handle until the mirror is brought to the required angle.

The rhinoscopic image is an extensive one, but the area of the mirror is very limited; consequently only a small portion can be seen at any one time, and it is necessary to introduce the mirror first on one side, then on the other side of the uvula, and to alter its position according to the part to be observed.

The complete rhinoscopic picture includes a variety of structures, each of which should be examined with considerable care. The cavity is divided into two parts by the septum nasi, the posterior edge of which is seen as a vertical line covered by a somewhat pale mucous membrane. From the lateral walls spring the superior middle and inferior turbinated bones, which are separated from each other by the three meatuses. The middle turbinated bone, with its pale mucous covering, appears the largest of the three, and is often separated by a very narrow interval from the septum. On the lateral walls are seen the triangular cushions which mark the position of the mouths of the Eustachian tubes, and which serve as such useful guides to the touch in catheterisation of these orifices. The floor of the cavity is formed by the soft palate, from the posterior border

of which hangs the uvula, the appearance of which is somewhat quaint, since it seems to be insufficiently supported from above.

The posterior wall of the pharynx and naso-pharynx should be quite smooth, and the roof of the nostril on each side should present the rounded form of a Roman arch when the parts are in their natural condition.

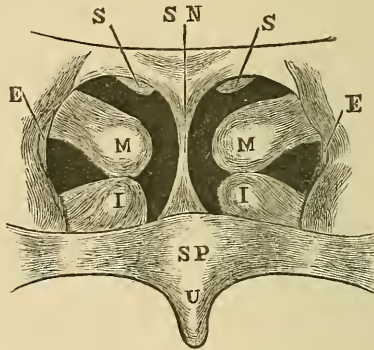


FIG. 17.—Posterior Rhinoscopic Picture.

S.N., Septum Nasi; S.S., Superior; M.M., Middle; I.I., Inferior Turbinated Bones; E.E., Eustachian Orifices; S.P., Soft Palate; U., Uvula.

It is only by constant and diligent practice that the beginner can hope to become proficient in the sister arts of laryngoscopy and rhinoscopy, and as he becomes more adept he will find the various difficulties which beset his path gradually melt away. This is especially the case with intolerance in patients, which is in most cases a result of clumsiness of the observer, and will in time be reduced almost to a vanishing quantity.

CHAPTER IX.

SYNOPSIS OF THE APPEARANCES IN THE CHIEF
LARYNGEAL DISEASES.

i. ACUTE LARYNGITIS—

Palate and fauces hyperæmic.

Epiglottis, ventricular bands, and aryteno-epiglottidean folds red and swollen.

True vocal cords very pink.

Sometimes imperfect closure of the glottis, owing to swelling of the parts.

ii. ŒDEMA—

Structures around the laryngeal orifice much swollen, hyperæmic, and translucent. Vocal cords little if at all affected.

iii. CHRONIC LARYNGITIS—

The signs of chronic pharyngitis are usually present.

The epiglottis, ventricular bands, and aryteno-epiglottidean folds somewhat thickened and hyperæmic.

True vocal cords of a yellowish pink colour, thickened and often irregular at their edges.

In later stages—Thickening of the laryngeal surface of the interarytenoid fold, preventing

complete apposition of the arytenoid cartilages, appearing as a whitish line.

Paralysis of the intrinsic muscles of the cords, causing want of tension and incomplete closure of the ligamentous glottis.

Sometimes adductor paralysis.

iv. TUBERCULAR LARYNGITIS—

Palate and fauces anæmic.

Pyriform swelling of the aryteno-epiglottidean folds.

General anæmia of the larynx with local hyperæmia.

Later—Turban-shaped swelling, with ulceration of the epiglottis, ulceration of the aryteno-epiglottidean folds, ventricular bands and true cords.

Interarytenoid ulceration common, the margin of the ulcer appearing as an irregular thickening upon the laryngeal surface. (This condition must be carefully distinguished from the thickening seen in chronic laryngitis.)

Sometimes œdematous swellings.

Rarely tubercular tumours in various parts of the larynx.

v. SYPHILITIC AFFECTIONS OF THE LARYNX—

Secondary—

Often laryngitis associated with the inflammation of the pharynx.

Sometimes mucous tubercles on the laryngeal structures.

Tertiary—

Hyperæmia and ulceration of the epiglottis, aryteno-epiglottidean folds, ventricular bands, and true cords.

The ulcers are usually of gummatous origin. Sometimes ulceration of the palate and fauces, or perforation of the palate.

vi. MALIGNANT DISEASE—

Usually epitheliomatous.

Irregular swelling of the ventricular bands, epiglottis, or aryteno-epiglottidean folds. Sometimes cauliflower growths.

Ulceration may be the earliest sign.

Later—Ulceration of the swollen portions, with formation of fungous growths.

Swelling of one ventricular band, or fixation of one vocal cord, whilst the other is unaffected, will excite suspicion.

Enlarged glands in the neck aid the diagnosis.

vii. INNOCENT TUMOURS—

(a) *Papilloma*—

Cauliflower excrescences, often very pale, springing usually from the true cords or the base of the epiglottis. When pedunculated they may cause death by obstructing the glottis.

(b) *Fibromata*—

Circumscribed, rounded tumours covered with pink mucous membrane.

(c) *Mucous Polypi*—

Small translucent swellings, covered with mucous membrane. When situated upon one true cord, the polypus gives to it a pink colour, the other cord remaining white.

viii. PARALYSES—

(a) *Functional Aphonia* (syn. *Hysterical Paralysis*)—

Paralysis of the adductors of both cords. The cords do not meet in phonation, but remain equidistant from the middle line.

(b) *One-sided Adductor Paralysis*—

The affected cord is widely abducted, and does not approach the middle line in phonation. The sound cord moves naturally.

Later—The sound cord crosses over to meet the paralysed one in phonation, its arytenoid lying to the front.

(c) *Paralysis of the Tensors*—

The vocal processes of the arytenoids meet in phonation, but a lenticular opening remains between the ligamentous cords. When the crico-thyroid is paralysed, the edges of the cords are wavy instead of straight.

(d) *Paralysis from pressure upon the recurrent laryngeal nerve.*

The abductor is first paralysed, and the cord remains near the middle line.

Later—Both abductor and adductors are paralysed, and the cord hangs half-way between adduction and abduction, in the so-called 'cadaveric' position.

The sound cord crosses to meet the paralysed one in phonation.

(e) *Paralysis of the Arytenoid Muscle*—

The ligamentous glottis is completely closed in phonation, but the cartilaginous portion remains patent and appears as a small triangular opening between the cartilages.

(f) *Abductor Paralysis*—

The affected cord is not abducted during inspiration, but its edge remains in the middle line.

Complete double abductor paralysis causes asphyxia.

(g) *Spasm of the Laryngeal Muscles*—

Laryngismus stridulus, common in children.

Adductor spasm may occur in later life.

The cords come together perfectly, but there is complete aphonia, the tension and close application of the cords preventing their vibration.

N.B. Mechanical fixation of the cords, the result of old inflammation, closely simulates paralysis. Other signs of old mischief will usually be present. The

beginner should be careful to distinguish such cases from true paralyses.

Once more : let him not allow a skew position of the throat mirror to lead him to a diagnosis of paralysis where none exists. The diagnosis should be based upon the observation of the movements of the cords, not upon their appearance when at rest.

30 origin of a fallacy - figs

COLUMBIA UNIVERSITY LIBRARIES

This book is due on the date indicated below, or at the expiration of a definite period after the date of borrowing, as provided by the rules of the Library or by special arrangement with the Librarian in charge.

| DATE BORROWED | DATE DUE | DATE BORROWED | DATE DUE |
|---------------|------------|---------------|----------|
| | SEP 2 1954 | | |
| 13 | | 5-5-1 | |
| | | | |
| | | | |
| | | | |
| | | | |
| | | | |
| | | | |
| | | | |
| | | | |
| | | | |
| | | | |
| | | | |
| | | | |
| | | | |
| | | | |
| | | | |
| | | | |
| | | | |
| | | | |
| | | | |
| | | | |
| | | | |
| | | | |
| | | | |

RC786

S.P.

G19

Garrod

An introduction to the use of
the laryngoscope

RC 786

G 19

3

108A

FINK

